

Report - International Scholar Award (ILTS) 2018

*Amanda Pinter Carneiro da Silva Boteon, MD, FEBS
Liver Unit Queen Elizabeth Hospital Birmingham- UK*

Institution: Division of HB surgery and Liver transplant, Department of Surgery, Ulsan University and Asan Medical Center (AMC), Seoul, Korea

Supervisor: Professor and Chief Ki-Hun Kim, MD, PhD

It is with great pleasure that I am submitting the final report from my International Liver Transplantation Society (ILTS) Travel Scholar Award successful application in 2018. I would like to mention that I have achieved my primary goals with this travel award, including undoubtedly opportunity to be exposed to living donor liver transplantation (LDLT) in an outstanding high-volume centre, wherein remedy a constraint in my training and helped to develop my expertise in LDLT. Apart from that, this training period in AMC, offered me the unique opportunity to gain more experience in HPB surgery, especially in complex cases and laparoscopic liver resections.

AMC has recorded the largest number of organ transplantation numbers in Korea and the largest number of LDLT cases in the world. As a background history, since the first LDLT in December 1994 until August 2018, the liver transplant team of AMC has successfully performed 5,000 LDLTs, which was the largest number of LDLT performed in the world. Also, AMC has been the No. 1 in the world with regards the following significant achievements: liver transplantation using a right lobe graft with middle hepatic vein reconstruction (1999), dual-graft living liver transplantation (2000), donor exchange program in liver transplantation between ABO incompatible group (2003). More important than that, with a genuine and unique hard working team, AMC has one-year survival rate of liver transplant patient of 98%.

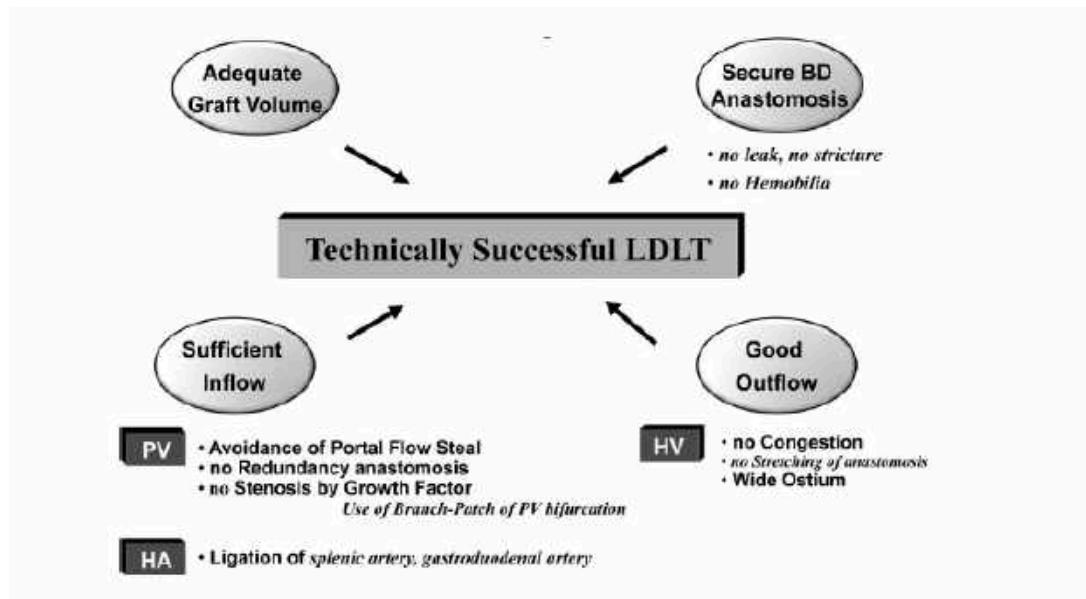
Considering the amazing experience the AMC team has, as partially summarized above, I would like to report my gaining experience into three different major points:

- LDLT;
- Laparoscopic Living donor hepatectomy and liver resection;
- Leadership and team work.

LDLT

The growing disparity between the number of liver transplant candidates and the supply of deceased donor organs has motivated the development of living donor liver transplantation especially in eastern-Asian countries, as South Korea, where culturally organ donation is not well accepted.

A major concern in adult living donor liver transplantation (ALDLT) is determining the graft size that can be safely harvested from donors. Also, better understanding of the complex surgical anatomy and physiologic differences of ALDLT helps avoid small-for-size graft syndrome, graft congestion from outflow obstruction and graft hypoperfusion from portal flow steal. Based on that, important principles and numerous technical aspects in the liver transplant surgery has been created and constantly reinforced in the routine practise of AMC which clearly improve and master good results. This chart bellow, published before by Lee at al in 2014 , is the main summarized example that routinely is followed in AMC and I will carry on my practise in the future:



Furthermore, this fellowship experience enhanced my learning regarding ensuring donor safety as a prime objective and therefore strict and careful donor selection is required. According to AMC guidelines:

- ≤35 years and no fatty change
- 30% remnant liver volume (RLV): Acceptable
- ≤35 years and ≤15% fatty change
- 30-35% RLV: Acceptable
- ≤35 years and ≤30% fatty change
- ≥35% RLV: Acceptable
- 35-55 years and ≤15% fatty change
- >35% RLV: Acceptable

- Adequate graft volume
- A) GRWR >1%
 - B) GRWR >0.8% + Young Donor (<35 years)
 - C) GRWR >0.7% + Young Donor + low MELD (<20)

Apart from preoperative volumetric measurement of the RLV, estimation of liver quality by preoperative US-guided liver biopsy must be assessed prior if the BMI is >25, the AST/ALT are >30 IU/L, the indocyanine green retention rate at 15 min (ICG R15) is >20%, the computed tomography (CT)/magnetic resonance is

suggestive of steatosis, the donor age is >35 years or the RLV is calculated to be marginal even with normal even with normal liver function.

Other important learning aspects regarding LDLT during my stay were: technical aspects and indication for dual-graft liver transplant as a strategy to expand ALDLT, innovative perioperative management tools to overcome ABO- group incompatibility such as the use of rituximab, plasmapheresis and triple immunosuppression therapy (tacrolimus, mycophenolate mofetil and steroids) as an option of shortage of deceased donors especially in patients with MELD < 30. Furthermore, the issues related to LDLT for HCC as it is already known its higher recurrence rates in this setting and also, their experience and results regarding expanded selection criteria for LDLT for patients with advanced HCC as well as the feasibility of salvage LDLT for recurrence HCC.

Laparoscopic living donor hepatectomy and liver resection

Laparoscopic liver resection (LLR) has been progressively increased used as surgical technique with also expanded indications including malignant tumours in unfavourable location and HCC resections in cirrhotic patients. During my stay in AMC, key points regarding LLR were always reinforced which definitely will change my practise and improve my outcomes and patient care:

1. Preoperative indication and evaluation: Imaging study, indocyanine green retention rate (ICG), routine bloods, tumour markers and esophagogastroduodenoscopy to verify the presence of varices. Indication for liver LLR should be performed for patients with preserved liver functions with sufficient remnant liver volume and without signs of severe portal hypertension or evidence of extra hepatic metastasis;
2. Surgical technique: Importance of port position depending on resection site, the use of pringle maneuver with an endo-bulldog clamp, glissonian pedicle approach parenchymal transection with CUSA and thunderbeat, specimen retrieval method;
3. The use of the extraglissonian approach to the hilar structures for pedicle transection and selective clamping;
4. Keep CVP lower during transection less than 5 cmH₂O and the intrathoracic pressure at approximately 20 cmH₂O without positive end-expiratory pressure;
5. Good equivalent short and long term outcomes in LLR for HCC;
6. Surgeon's experience and keep oncological principles are really important for good outcomes in LLR;

In the field of laparoscopic living donor hepatectomy it has been very clear and well emphasized and I also believe it is very important for successful outcomes is that strict indication is vital for ensuring donor safety. In AMC indication for laparoscopic donor right hepatectomy (LSRH) includes: single and longer segments of right hepatic artery, right portal vein and the right hepatic duct. Secondly, fewer segments 5 and 8 veins, not a sizeable inferior right hepatic veins and finally graft weight less than 700 g. Furthermore, It was very important learning point the constant

use of both intra operative colangiogram and indocyanine green for the proper identification of the biliary tree and the precise cutting point in the setting of laparoscopic living donor operation.

Leadership and teamwork

One of the most outstanding points in AMC is teamwork and this I could experience clearly that this is the key in liver transplantation for maintaining the highest quality with outstanding outcomes. A multidisciplinary approach with surgical, radiological and medical teams, and institutional support, is crucial. The example and continuous dedication from a good leader like Prof Sung-Gyu Lee enhances and brings up dedicated staff including surgeons, intensivists, hepatologists, radiologists and nurses which finally will provide the best performance with the main objective being patient care.

Apart from this previously mentioned points, I had the opportunity to participate in the 7th Biennial Congress of the Asian-Pacific Hepato-Pancreato-Biliary Association (A-PPBA 2019) and in the 2019 Seoul Paediatric Liver Transplantation Society where I broaden my knowledge on those fields especially taking into account that the majority of lectures were presented by great experienced professors from Asia.

Also, I must report the incredible personal and professional learning experience facing a completely new different language and culture within the world's largest LDLT program in South Korea.

To conclude, this award provided me a unique opportunity to gain experience and develop my skills with LDLT at one of the best centres worldwide, and in combination with my current skills in multi-organ retrieval and deceased donor liver transplantation, I will be aided accomplishing my career goal of becoming a successful Adult and Paediatric Liver Transplant and Hepatobiliary Surgeon.

Acknowledgments

Firstly, I would like to express my endless gratitude to Prof Ki-Hun Kim for being extremely helpful, considerate and friendly mentor during my stay in AMC. He is an excellent and skilled surgeon and a fabulous person, which I have learned enormously from and undoubtedly will impact highly positive in my career. His hospitality and generosity are unique and unforgettable.

Secondly, I want to thank all the AMC liver transplant surgeons, fellows, surgical assistants and nursing staff for receiving me in the team openly and kindly.

Pictures



