

First Cases of COVID-19 in Heart Transplantation From China

Fei Li, *Jie Cai, *Nianguo Dong

Department of cardiovascular surgery, Union Hospital, Tongji Medical College,
Huazhong University of Science and Technology

*Correspondence to: Nianguo Dong, Department of cardiovascular surgery, Union
Hospital, Tongji Medical College, Huazhong University of Science and Technology,
Wuhan, 430022, China, Email: dongnianguo@hotmail.com; or Jie Cai, Department of
cardiovascular surgery, Union Hospital, Tongji Medical College, Huazhong University
of Science and Technology, Wuhan, 430022, China, Email: cjdoctor@163.com

Emerging studies suggest that the novel coronavirus SARS-CoV-2 and the disease it causes, COVID-19, selectively afflicts the elderly, particularly those with chronic comorbidities.^{1,2} Here, we report on two heart transplant recipients with COVID-19, one a severe presentation and another mild.

The first was a 51-year-old man with a heart transplant on November 8th, 2003. His immunosuppression was tacrolimus 1 mg twice daily plus mycophenolate mofetil 0.5 g twice daily. The last known blood concentration of tacrolimus was 6.5 ng/ml, and cardiac allograft function was normal with a history of well controlled hypertension. On Jan 23rd 2020, he complained of intermittent fever, chills, fatigue, poor appetite and diarrhea. On examination, his temperature was 38.5°C, oxygen saturation was 99% on room air, respiratory rate of 20 breaths per minute without distress. Laboratory tests showed a white blood cell count of $4.87 \times 10^9 /L$ (normal range, $4.0\text{--}10.0 \times 10^9 /L$), C Reactive Protein of 18.6 mg/L (normal range, 0-10 mg/L). Chest computed tomographic (CT) scan showed bilateral ground-glass opacities (Figure 1). He was initially treated with intravenous levofloxacin and ribavirin, but remained febrile. He was admitted to Wuhan Fifth Hospital on Jan 26th 2020 and a throat swab nucleic acid test was positive for 2019-nCoV. Moxifloxacin 0.4 g and ganciclovir 0.25 g were then given intravenously daily (and continued until Feb 5th 2020). Initially, his temperature rose to 39°C with a dry cough on Jan 27th,2020 and oxygen saturation decreased gradually requiring oxygen nasal supplementation. Body temperature dropped to normal on Jan 29th, however oxygen saturation deteriorated, (75% without supplemental oxygen after slight activity). CT scan revealed worsening of lung lesions

(Figure 1) and oxygen was given through a face mask with improvement of oxygen saturation to 95%. Intravenous human gamma globulin 10 g / day plus methylprednisolone 80 mg/day for initiated for 5 consecutive days and other immunosuppressive drugs were held from Jan 30th to Feb 5th, 2020. After treatment, the patient's symptoms improved, and oxygen saturation maintained above 96% with nasal cannula oxygen. Intravenous medications were then stopped, and oral administration of moxifloxacin 0.4 g/day and arbidol (a non-nucleoside antiviral and immunomodulating drug given for influenza), at a dose of 0.2 g three times a day was administered for 5 days. Immunosuppressive and antihypertensive drugs were resumed on Feb 12th, 2020. The patient's temperature normalized for more than 20 days, without cough for 10 days and preserved oxygen saturation. Two consecutive RT-PCR throat swabs for 2019-nCoV on Feb 14th and 18th 2020, were negative. CT scan on Feb 24th showed significant resolution of lung lesions (Figure 1). The patient was discharged on Feb 27th 2020. Typical imaging demonstrated dynamic progress of the disease (Figure 1). However, resolution of lung lesions lagged behind symptoms relief.

A second heart transplant male recipient aged 43-years old presented to the outpatient clinic with fever for 2 days on Jan 25th 2020, exhibited mild lung lesions on CT scan, but a nucleic acid test for 2019-nCoV was positive. The patient was quarantined at home and then admitted to the hospital on Feb 6th, 2020 following which he was discharged on Feb 11th when two nucleic acid tests for 2019-nCoV tested negative. (Detailed information on this patient is in Table 1).

These cases may represent the first descriptions of COVID-19 in heart transplant

recipients and suggest that presentations appear to be similar to those observed in non-transplant recipients. We have also followed 200 heart transplant patients in Hubei area by telephone and found a third confirmed patient who is currently under treatment in another hospital, but the case details are not available to us and therefore not included in our report. Whether organ transplant recipients are more susceptible to COVID-19 requires further large-scale epidemiological investigation, but the presentation pattern and resolution of the disease using the described supportive measures may serve to inform direction of care if such patients are encountered elsewhere.

Conflicts of interest and Funding: None.

Acknowledgement: We are indebted to Dr. Qing Wu and her team of Wuhan Fifth Hospital for the diagnosis and treatment provided to the first patient.

References:

1. Wang D, Hu B, Hu C, et al. Clinical Characteristics of 138 Hospitalized Patients With 2019 Novel Coronavirus-Infected Pneumonia in Wuhan, China. *JAMA*. Published online February 7, 2020. doi:10.1001/jama.2020.1585
2. Yang X, Yu Y, Xu J, et al. Clinical course and outcomes of critically ill patients with SARS-CoV-2 pneumonia in Wuhan, China: a single-centered, retrospective, observational study. *Lancet Respir Med*. Published February 24, 2020 DOI:[https://doi.org/10.1016/S2213-2600\(20\)30079-5](https://doi.org/10.1016/S2213-2600(20)30079-5)

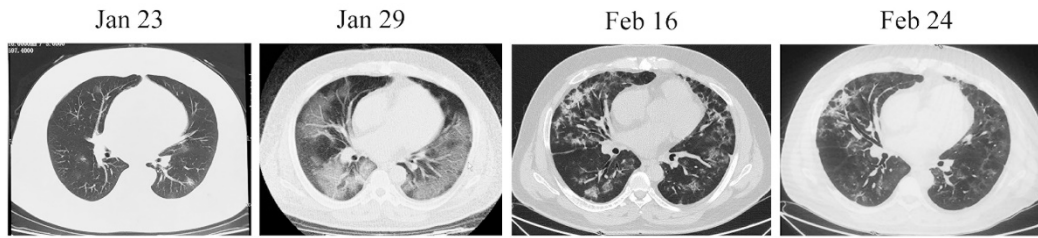


Figure 1. Dynamic chest CT manifestations of severe COVID-19 in a heart transplant recipient.

Table 1. Clinical characteristics of the second patient

Date of transplant	May 17 th , 2017
Immunosuppression	Tacrolimus 1.5 mg in the morning, 2 mg in the evening mycophenolate mofetil 0.5 g twice daily
Blood concentration of tacrolimus	8.3 ng/ml
Allograft function	Left ventricular ejection fraction 64%
Comorbidities	Hyperlipidemia and impaired glucose tolerance
Lab test	on Jan 25 th 2020, WBC 8.2×10^9 /L, Lymphocyte 0.8×10^9 /L, CRP 13.4 mg/L on Feb 7 th 2020: WBC 8.4×10^9 /L, Lymphocyte 1.5×10^9 /L, CRP 1.0 mg/L
RT-PCR of 2019-nCoV (throat swab)	Positive on Jan 28 th , negative on Feb 8 th and 10 th
Treatment	Ceftriaxone sodium 2.0 g and ganciclovir 0.25 g intravenously (Jan 25 th to 31 st) ; Oral moxifloxacin 0.4 g/day and arbidol 0.2 g three times a day (Feb 1 st to 10 th)
Symptoms evolution	Fever for two days, up to 38.5 degrees C Fatigue and poor appetite from Jan 28 th to Feb 5 th
Rejection during or after COVID-19	None
Other Complications	None